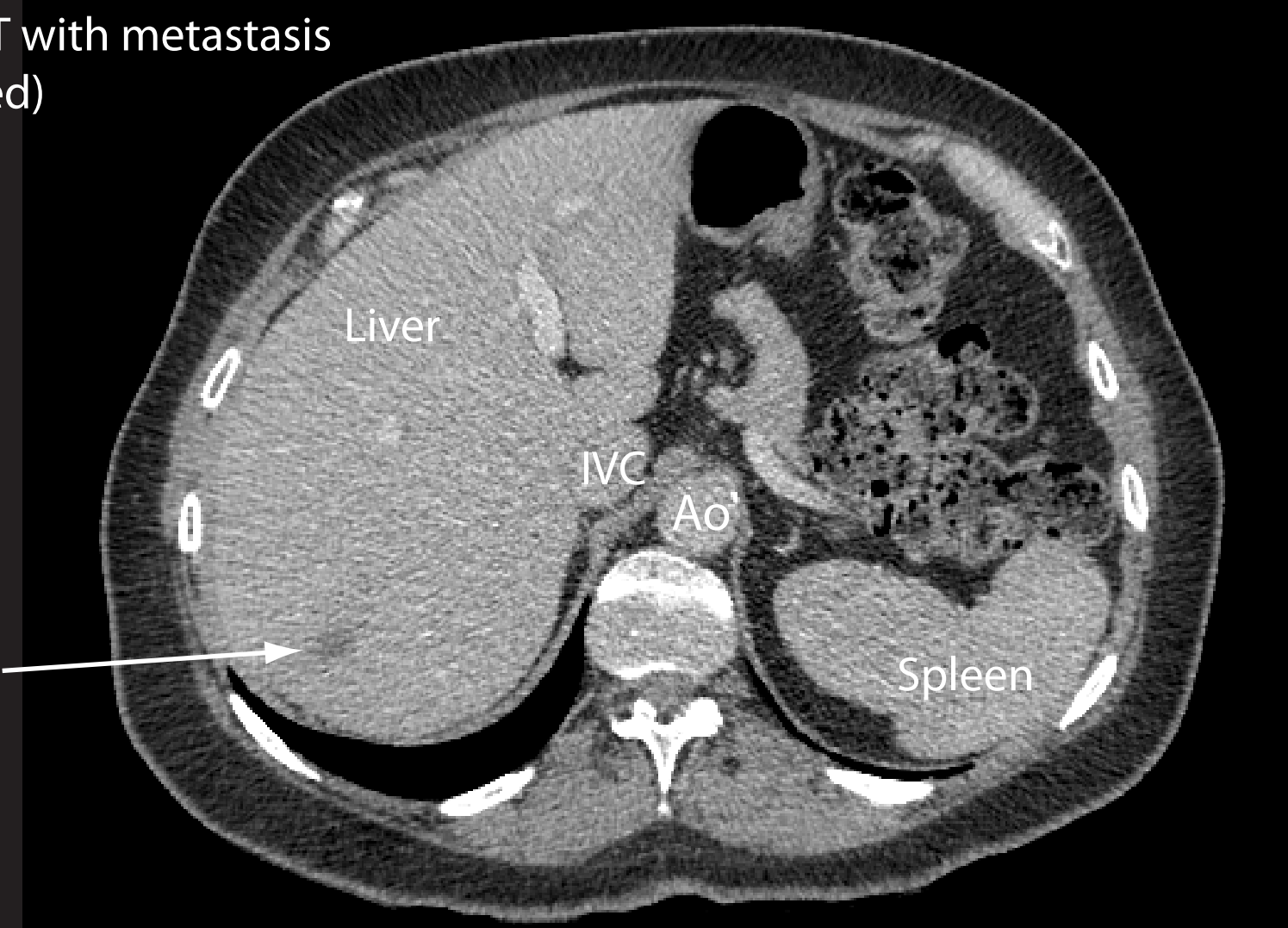


Colorectal metastasis in right lobe of liver detected 1 year after resection of a rectal carcinoma. There was no nodal spread at the time of anterior resection of the rectum, with the cancer being graded as a Dukes' B at the time.

Portal phase axial CT with metastasis in right lobe (arrowed)



PET CT with metastasis highlighted as an area of intense metabolic activity (yellow). No other metastases were noted.

